

Xoft, a subsidiary of iCAD, Inc.

HDR Electronic Brachytherapy

A Non-surgical Treatment Alternative for
Non-melanomatous Skin Cancer

White paper

Rakesh Patel, M.D., Ajay Bhatnagar, M.D.,
Philip Werschler, M.D., Roger Ceilley, M.D.
April 2015

High Dose Rate Electronic Brachytherapy:

A Non-surgical Treatment Alternative for Non-melanomatous Skin Cancer

Background

Non-melanomatous skin cancers (NMSC) are a global problem and represent the most common cancers diagnosed in the United States each year with an estimated 3.5 million new cases.¹ Cancer of the skin typically occurs in sun-exposed areas of the body in older adults and the incidence increases every year.² This has translated to a significant increase in the number of new skin cancer procedures being performed per year (estimated 5% growth per year).³ Fortunately, most NMSC lesions are detected at an early stage that is amenable to very effective local therapy and thus are highly curable.

Treatment Paradigms

Primary care physicians and general dermatologists manage most NMSC in their office. The specific modality chosen is dependent on a combination of clinical and pathologic factors and has varying degrees of effectiveness. These include specific squamous or basal cell histologic subtypes, size, lesion grade, location, treatment history and patient preference. Historically, most patients with early stage skin cancer have been treated with destruction, including cryosurgery, electrodesiccation and curettage (ED&C), and simple excision. Although several topical chemotherapeutic options are available, as is gene therapy (bcc), these have not been widely employed because of concerns over effective cure rates or tolerance of side effects.

Mohs micrographic surgery, an advancement in surgical technique specific to NMSC, removes cancerous tissue in a precise fashion utilizing histologic margin control. The surgical margins are carefully evaluated in a staged fashion, with careful inking and mapping combined with horizontal tissue sectioning, as opposed to vertical (breadloaf) sectioning.

This allows for near 100% examination of the surgical margin. This process is repeated until the tumor bed is cleared in both peripheral and deep planes. The result is optimal preservation of healthy tissue integrity compared to removal of larger volumes with simple excision.

The long term clearance rates for this “microscopic” or “micrographic” procedure are generally considered to be excellent with 5-year clearance rates



that approach 99% for primary BCC^{4,5,6,7} and 97% for primary SCC⁸ and can be as low as 93% for large and aggressive or recurrent BCC^{9,10,11} or 90% for locally recurrent (previously treated) SCC¹², and 68% for poorly differentiated SCC.¹² This specific technique requires specialized training gained either through fellowship or post graduate training.¹³ Among the drawbacks for this procedure are specialized equipment, staff, training and facilities. For patients, the procedure requires a minimum of several hours of in-office wait times, in addition to a separate surgical procedure in most instances to close the surgical defect. In some larger or more complicated cases, the addition of hospital or outpatient surgery center facilities are required, along with the expertise of plastic surgeons to complete the reconstruction process.

Cryotherapy, photodynamic therapy, or topical chemotherapeutic agents represent other treatment alternatives.^{14,15,16} These treatments have inherent technical and logistical limitations in target coverage that have resulted in higher local recurrence rates including an inability to penetrate deeper layers and patient non-compliance.

The Role of Radiation Therapy

The NCCN (The National Comprehensive Cancer Network) guidelines suggest that in a review of literature, the best results for NMSC were obtained with Mohs surgery. However, consideration of function, cosmetic outcome, reduced scarring and patient preference may lead to radiation therapy as the primary treatment choice in order to achieve optimal overall results. Therapeutic x-rays have been used for the primary treatment for skin cancer for nearly a century. First generation machines were costly to maintain, and resulted in more collateral exposure of nearby healthy tissues. Newer superficial radiation therapy machines have been developed; however this technique still delivers greater doses to tissues at depth thereby typically requiring a lengthy 15-30 daily treatment course. This is especially problematic for surface lesions in cosmetically sensitive locations or those with nearby critical structures.

Modern electron beam radiation therapy is more readily available and allows three-dimensional treatment planning. However, there are challenges with dosimetry of irregular or curved surfaces and the technique requires a broader surface area to be irradiated over long courses than with more targeted techniques, such as HDR brachytherapy.



The Advantages of High Dose Rate Surface Brachytherapy

High-dose rate (HDR) surface brachytherapy can be delivered with either a radioactive source (typically Iridium-192) or with an electronic, miniaturized x-ray source. The brachytherapy source is placed in close proximity to the target lesion with specialized applicators using a specialized machine called a remote afterloader for Iridium-192 isotope treatment or a controller that provides the energy and controls the treatment for electronic brachytherapy treatments. The size of the applicators and shape of the target area can be tailored to the complexity and extent of the skin lesion. This technique can be used for all NMSC subtypes as well as keloids.

Total Dose (Gy)	# Fractions	Dose Per Fraction (Gy)
42	6	7.0
40	8	5.0
40	10	4.0

Common HDR Surface Brachytherapy Dose/Fractionation Schedules

A key advantage of HDR brachytherapy is that it maximally spares adjacent, deeper healthy tissues due to a rapid falloff of the customized, surface radiation dose. Therefore, the treatment courses are typically much shorter and more convenient. The treatment is noninvasive and therefore does not require needles, cutting, or sutures. This causes less scarring in sensitive facial areas such as the nose, ear, lip, or eyelid and less need for reconstructive procedures for tissue destruction. This is a distinct advantage especially in those with difficulty in wound healing such as patients that are elderly, have diabetes, peripheral vascular disease or if they are on anti-coagulants.

An innovative type of HDR surface brachytherapy is HDR electronic brachytherapy (eBx), which combines the benefits of traditional isotopic brachytherapy with those of low-energy X-ray radiotherapy. In this technique, a high dose rate (HDR) X-ray source is placed directly into a skin applicator close to the surface and provides a homogenous dose pattern in the treatment area to a specified depth, typically 3-mm. In contrast, iridium-based HDR surface brachytherapy using the Leipzig applicator requires increased margin to adequately treat the lesion due to its larger penumbra. This can be critically important for treating sensitive locations such as the nasal tip, nasal ala, eye canthus, eyelid, and ear where there is minimal space to allow for additional margin.



HDR electronic brachytherapy allows delivery outside of radiation oncology facilities due to minimal shielding requirements since isotopes or megavoltage linear accelerators are not used. The mobility of the system increases access for patients as it can be transported between multiple rooms or facilities.

The short, few-minute HDR electronic brachytherapy treatments are typically delivered over an accelerated 8-10 treatment course twice weekly to 40 Gy. The treatments are typically pain-free and well tolerated with fast recovery times relative to protracted external beam radiotherapy (EBRT) during which schedules are frequently 20-30 daily fractions to 50-60 Gy.

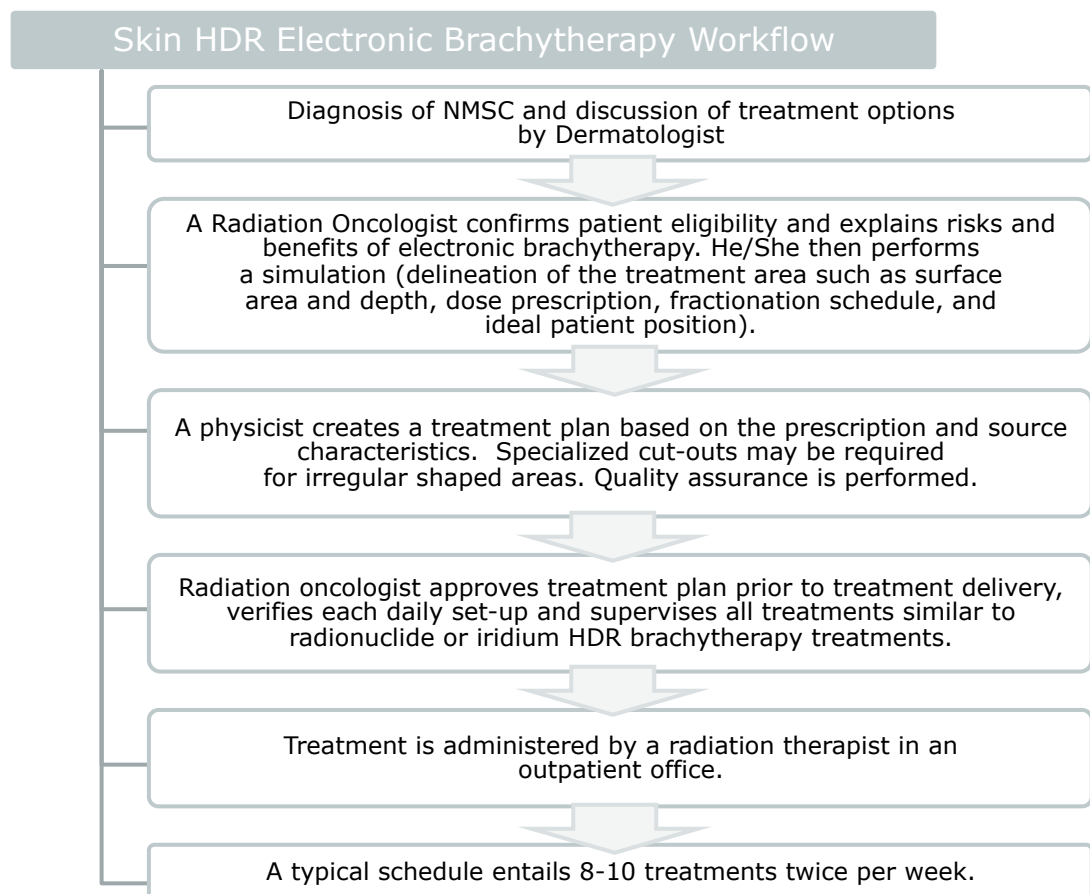


Figure 1. HDR Workflow

Patient Selection

HDR surface brachytherapy has demonstrated excellent local control rates for Basal and Squamous Cell Carcinoma in appropriately selected patients.^{17,18}

This includes complex lesion locations such as those in cosmetically sensitive areas of the face including the nose, eyelids, lips, ears, or in parts of the body



with thin, delicate tissue that could lead to surgical healing problems such as the pretibial area of the leg or the dorsum of the hand. The lesions typically are less than 4 cm diameter and less than 5 mm depth.

HDR electronic brachytherapy may also be preferable in elderly patients with health issues such as peripheral vascular disease, diabetes mellitus or those on anti-coagulants in which case anesthesia and surgery may be contraindicated. For patients with dementia, psychiatric illness, anxiety disorders and for those with personal objections that may interfere with prolonged in-office surgical procedures, HDR electronic brachytherapy can be performed as primary radiation therapy or can be used as an adjunct to surgery for higher risk lesions including features such as positive margins or perineural invasion.

Outcomes

The control rates of non-melanoma skin cancer after HDR electronic brachytherapy, with both isotopic and electronic sources, cited in the literature are generally very high with minimal toxicity for favorable patients.^{19,20,21,22} During the treatment course, patients may develop mild skin rash, itching and dryness limited to the lesion area. They typically resolve within a couple weeks of completing therapy.

Several studies have reported excellent local control rates (>95%), and favorable cosmetic outcomes with minimal long-term side effects for HDR electronic brachytherapy. More specific data are summarized below in the table.

Combined Published Data for HDR Electronic Brachytherapy March 2015

Treatment Period	July 2009-August 2014
# Patients	875
# Lesions	1,238
Age (Years)	
Mean Age	74.8
Median Age	80
Histopathology	
BCC	796
SCC	419
Staging	
T1	198
T2	3



Primary/Recurrent	
Primary	186
Recurrent	16
Lesion Size (cm)	
<1 cm	472
1-2 cm	490
2-3 cm	22
3-4 cm	4
4-5 cm	1
Lesion Location (N/R = Not Reported)	
Face (may include forehead, temple, eyelid, cheek, glabella, lips, chin, sideburn and ear)	306
Nose	315
Ear	58
Scalp	173
Neck	12
Trunk	115
Upper/lower Extr.	215
Treatment	
Total Dose (Gy)	40-45
Fractions	8-10
Tx depth (mm)	
≤2	672
3	402
≥4	2
Follow-up	
Lesion Follow-up Range (Months)	0-63
< 1 Year	688
1-2 Years	103
2-3 Years	51
3-4 Years	35
4-5 Years	12
> 5 Years	0
Results	
Cosmesis	Good to Excellent
Recurrence	1-3 lesions per study 0.34%-0.61%

Note: Not all sources of data reported results for each criteria



Publications:

1. A. Bhatnagar, MD, MBA, Cancer Treatment Services Arizona, Affiliate of 21st Century Oncology, Casa Grande, AZ, University of Pittsburgh, School of Medicine, Pittsburgh, PA, *Electronic Brachytherapy for the Treatment of Non-melanoma Skin Cancer: Results up to 4 Years*, 73rd Annual Meeting of the American Academy of Dermatology, San Francisco, CA, March 20-24, 2015
2. R. Patel, MD, Gordon Wong, MD, Yuriko Minn, MD, Dharanirajan Rajendra, MS, Sujatha Pai, MS, *The Targeted Radiation Institutes @ VMOC, Pleasanton, CA, Initial Experience with Electronic Brachytherapy for Skin Cancer: Clinical and Dosimetric Characteristics*, Poster PO44 American Brachytherapy Society, Annual Meeting, San Diego, CA, April 3-5, 2014
3. P. Sanghvi, MD, MSPH, Assistant Clinical Professor, Chief, Leukemia/Lymphoma and Cutaneous Malignancies, Department of Radiation Medicine and Applied Sciences, UCSD, *Electronic Brachytherapy for Non-Melanoma Skin Cancers (NMSC) (Presentation)* American Brachytherapy Society, Annual Meeting, San Diego, CA, April 3-5, 2014
4. R. Strimling, MD, FAAD, Strimling Dermatology, Laser, Vein Institute, Las Vegas, NV, *Initial Experience of Electronic Brachytherapy for the Treatment of 494 Non-melanoma Skin Cancer (NMSC) Lesions in 297 Patients*, 73rd Annual Meeting of the American Academy of Dermatology, San Francisco, Ca March 20-24, 2015

The Collaborative Model: Dermatologists and Radiation Oncologists

HDR electronic brachytherapy is a highly effective non-surgical alternative for a broad array of patients with non-melanomatous skin cancer. It is essential for the dermatologist and radiation oncologist to collaborate on selecting the ideal patients, enable precise treatment planning and in turn offer high-quality eBx delivery with optimal outcomes and clinical efficiency. There are clear benefits when both the dermatologist and radiation oncologist are involved with this modality utilizing their unique expertise respectively.

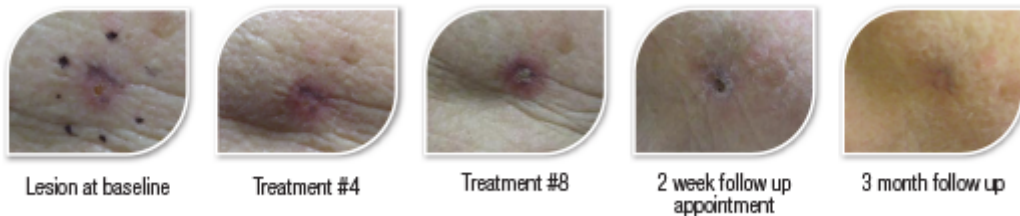
The dermatologist helps to identify potential candidates for electronic brachytherapy and can often help delineate the skin target lesion. The radiation oncologist is critical in delivering this treatment and properly counseling the patient on the risks and benefits as well as obtaining informed consent for this procedure. This collaborative approach allows for optimal patient care and patient satisfaction.



Clinical Examples

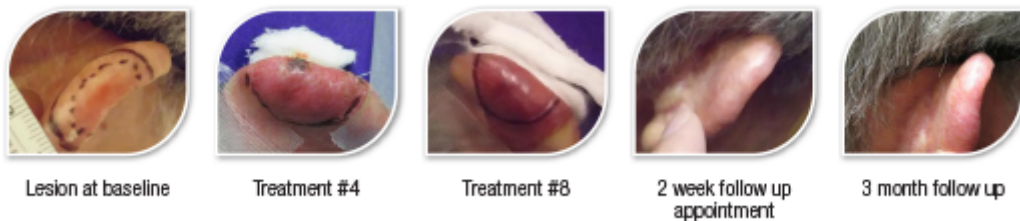
Case #1: Jawline

73-year-old female with a nodular squamous cell carcinoma on the right jawline. Lesion size was 5mm x 5mm and treated with 10mm cone @ 3mm depth, 500cGy x 8. eBx was chosen because the patient was unable to stop use of anti-coagulants for treatment.



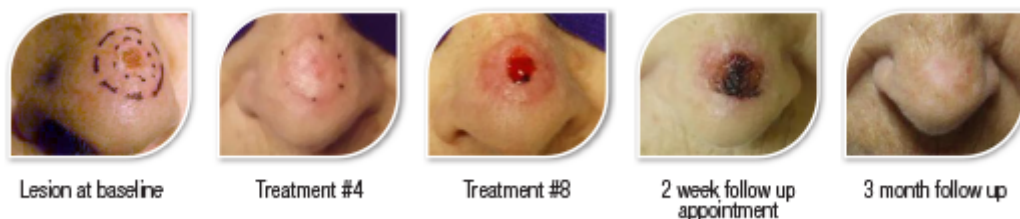Case #2: Ear

78-year-old male with infiltrative basal cell carcinoma on the right helical rim. Lesion size was 12mm x 9mm and treated with a 20mm cone @ 3mm depth, 400cGy x 10. Mohs would have required removal of part of the ear, therefore eBx was chosen for cosmetic reasons.



Case #3: Nose

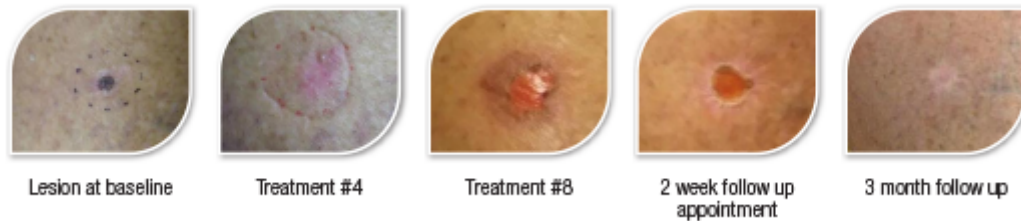80-year-old female with a nodular squamous cell carcinoma on the nose. Lesion size was 8mm x 9mm and treated with a 20mm cone with 15mm cutout @ 3mm depth, 500cGy x 8. eBx was used due to the location of the lesion presenting a cosmetic reconstruction challenge.



Case #4: Left Shin

76-year-old female with infiltrative basal cell carcinoma on the left shin.

Lesion size was 13mm x 14mm and treated with a 20mm cone @ 3mm depth, 400cGy x 10. Mohs would have required removal of part of the shin, therefore eBx was chosen for cosmetic reasons.



Images courtesy of Jonathan Baron, M.D., Santa Ana, CA

-
- 1 Rogers HW, Weinstock MA, Harris AR, et al. Incidence estimate of nonmelanoma skin cancer in the United States, 2006. *Arch Dermatol* 2010;146:283-287.
 - 2 American Cancer Society. <http://www.cancer.org/Cancer/SkinCancer-BasalandSquamousCell/detailed-Guide/skin-cancer-basal-and-squamous-cell-key-statistics>.
 - 3 National Cancer Institute. <http://www.cancer.gov/cancertopics/types/skin>.
 - 4 Hruza GJ. Mohs micrographic surgery local recurrences. *J Dermatol Surg Oncol*.1994 Sep;20(9):573-7.
 - 5 Mohs FE. Micrographic surgery for the microscopically controlled excision of eyelid cancers. *Jun*;104(6):901-9.
 - 6 Giordano Resti A, et al. Outcome of 110 basal cell carcinoma of the eyelid treated with frozen section-controlled excision: mean follow-up over 5 years. *Eur J Ophthalmol*. 2014 Jul-Aug;24(4):476-82.
 - 7 Malhotra R. The Australian Mohs database, part II: periocular basal cell carcinoma outcome at 5-year follow-up. *Ophthalmology*. 2004 Apr;111(4):631-6.
 - 8 Leibovitch I, Huilgol SC, et al. Cutaneous squamous cell carcinoma treated with Mohs micrographic surgery in Australia I: experience over 10 years. *J Am Acad Dermatol* 2005;53:253-60.
 - 9 Smeets NW, Kuijpers DL, Nelemans P, et al. Mohs micrographic surgery for treatment of basal cell carcinoma of the face-results of a retrospective study and review of the literature. *Br J Dermatol*. 2004 Jul;151(1):141-7.
 - 10 Wennberg AM, Larkö O, Stenquist B. Five-year results of Mohs micrographic surgery for aggressive facial basal cell carcinoma in Sweden. *Acta Derm Venereol*. 1999 Sep;79(5):370-2.



- 11 Smeets NW, Krekels GA, Ostertag JU, Essers BA, Dirksen CD, Nieman FH, Neumann HA. *Surgical excision vs Mohs' micrographic surgery for basal-cell carcinoma of the face: randomised controlled trial.* *Lancet.* 2004 Nov 13-19;364(9447):1766-72.
- 12 Rowe DE, Carroll RJ, Day CL Jr. *Prognostic factors for local recurrence, metastasis, and survival rates in squamous cell carcinoma of the skin, ear, and lip. Implications for treatment modality selection.* *J Am Acad Dermatol.* 1992 Jun;26(6):976-90.
- 13 Cumberland L, Dana A, Liegeois N. *Mohs micrographic surgery for the management of nonmelanoma skin cancers.* *Facial Plast Surg Clin North Am.* 2009 Aug;17(3):325-35.
- 14 Basset-Seguín N, Ibbotson SH, Emtestam L, Tarstedt M, Morton C, Maroti M, Calzavara-Pinton P, Varma S, Roelandts R, Wolf P. *Topical methyl aminolaevulinate photodynamic therapy versus cryotherapy for superficial basal cell carcinoma: a 5 year randomized trial.* *Eur J Dermatol.* 2008 Sep-Oct;18(5):547-53.
- 15 Rhodes LE, de Rie MA, Leifsdottir R, Yu RC, Bachmann I, Goulden V, Wong GA, Richard MA, Anstey A, Wolf P. *Five-year follow-up of a randomized, prospective trial of topical methyl aminolevulinate photodynamic therapy vs surgery for nodular basal cell carcinoma.* *Arch Dermatol.* 2007 Sep;143(9):1131-6.
- 16 Berking C, Hauschild A, Kölbl O, Mast G, Gutzmer R: *Basal cell carcinoma – treatments for the commonest skin cancer.* *Dtsch Arztebl Int* 2014; 111: 389–95. DOI: 10.3238/arztebl.2014.0389
- 17 Petrovich Z, Kuisk H, et al. *Treatment results and patterns of failure in 646 patients with carcinomas of the eyelids, pinna and nose.* *Am J Surg* 1987. 154:447-450.
- 18 Gauden R, Pracy M, Avery AM, Hodgetts I, Gauden S. *HDR brachytherapy for non-melanoma skin cancers.* *J Med Imaging Radiat Oncol* 2013 Apr;5792:212-7.
- 19 Bhatnagar A. *Nonmelanoma skin cancer treated with electronic brachytherapy: Results at 1 year.* *Brachytherapy* 2013 Mar-Apr;12(2):134-40.
- 20 Caccialanza M, et al. *Radiotherapy of skin carcinomas of the pinna: a study of 115 lesions in 108 patients.* *IJ Dermatol* 2005.44:513-517.
- 21 Olschewski T, Bajor K, Lang B, Lang E, Seegenschmiedt MH. *Radiotherapy of basal cell carcinoma of the face and head: Importance of low dose per fraction on long-term outcome.* *J Dtsch Dermatol Ges.*2006 Feb;4(2):124-30.
- 22 Guix B, Finestres F, Tello J, Palma C, Martinez A, Guix J, et l. *Treatment of skin carcinomas of the face by high-dose-rate brachytherapy and custom-made surface molds.* *IJROBP* 2000;47:95-102.

